

## Echo-Doppler Demonstration of Acute Cor Pulmonale at the Bedside in the Medical Intensive Care Unit

Antoine Vieillard-Baron, Sebastien Prin, Karim Chergui, Olivier Dubourg, and François Jardin

Medical Intensive Care Unit, and Department of Cardiology, University Hospital Ambroise Paré, Assistance Publique Hôpitaux de Paris, Boulogne, France

For a long time, the only procedure available to the intensive care unit physician to assess cardiac function at the bedside was right heart catheterization. Right heart catheterization allows measurements of pressure and flow and the computation of derived variables. But these require an appropriate integration to obtain an accurate diagnosis. In other words, the aim of the quantitative evaluation obtained by right heart catheterization is to provide an indirect qualitative estimate of cardiac function. Conversely, echocardiographic evaluation is directly qualitative: by a simple visualization in real time of the kinetics and size of cardiac cavities, an experienced critical care intensivist with a sufficient echocardiographic background can immediately establish a functional diagnosis.

This clinical review aims at illustrating the valuable information provided by echocardiography for the assessment of cardiac function at the bedside. For that purpose, we have chosen a particular and well-defined clinical setting, acute cor pulmonale.

### ACUTE COR PULMONALE: DEFINITION

Acute cor pulmonale can be defined as a clinical setting in which the right ventricle is suddenly afterloaded. Massive pulmonary embolism and acute respiratory distress syndrome are the most common clinical conditions associated with acute cor pulmonale. In both settings, right ventricular (RV) outflow impedance is suddenly increased, RV ejection is impaired, and RV size is enlarged. Thus, acute cor pulmonale combines systolic and diastolic overload. Both are integrated in its echocardiographic definition, which includes septal dyskinesia (characterizing systolic overload), associated with right ventricular enlargement (characterizing diastolic overload) (1). Acute cor pulmonale may cause or precipitate circulatory failure in a critically ill patient.

### VENTRICULAR INTERDEPENDENCE

A brief review of this physiologic phenomenon is useful in understanding echocardiographic abnormalities observed in acute cor pulmonale.

Left and right ventricular systoles occur simultaneously, with the right and left ventricles starting and ending contraction al-

most at the same time. When right ventricular systole is overloaded, right ventricular contraction is prolonged, so that the right ventricle can continue to push after the left ventricle systole has ended (2). At this time, and for a short instant, the pressure in the right ventricular cavity may overcome that of the left ventricle, and reversal of the trans-septal pressure gradient imposes leftward displacement of the septal wall (Figure 1).

Left and right ventricles are both enclosed in a stiff envelope, the pericardium. Both ventricles have similar end-diastolic volumes, and there is no free space for ventricular dilatation in a normal pericardial space. Thus, when right ventricular diastole is overloaded, right ventricular enlargement can occur only at the expense of the space devoted to the left ventricle, which is thus restricted.

### DESCRIPTION OF MAIN ECHOCARDIOGRAPHIC VIEWS USED TO STUDY RIGHT VENTRICULAR FUNCTION IN AN INTENSIVE CARE UNIT

Echocardiographic examination of the right ventricle requires a long-axis view to evaluate the size of the cavity and a short-axis view to evaluate septal kinetics (Figure 2), a Doppler examination of blood velocity in the outflow tract, and an examination of the inflow tract, including inferior vena caval size, and blood velocity of backward flow across the tricuspid valve, if present. The interventricular septum may also be examined on an oblique plane parallel to its long axis (Figure 2).

When breathing is spontaneous, as is usually the case in patients exhibiting massive pulmonary embolism, the right ventricle can be examined via a transthoracic approach. When the patient is mechanically ventilated, which is always the case in acute respiratory distress syndrome, right ventricular evaluation should be performed via a transesophageal approach, which provides better imaging in this setting.

Echocardiography is essentially a qualitative procedure. However, quantitative measurements may be useful, and examples are given in this article. We have thus tested the reproducibility of the main measurements used in our laboratory to assess right ventricular function (Table 1).

Because severe hypovolemia may influence right ventricular size, this disorder should be corrected before echocardiographic examination. Any hypovolemia can be easily recognized during examination (3, 4) and corrected by rapid volume expansion, before pursuing measurements.

### ECHO-DOPPLER DEMONSTRATION OF RIGHT VENTRICULAR SYSTOLIC OVERLOAD: SEPTAL DYSKINESIA

As mentioned above, right ventricular systolic overload increases the duration of right ventricular systole, although the right ventricular ejection period may be reduced. Prolongation of right

(Received in original form February 25, 2002; accepted in final form September 23, 2002)

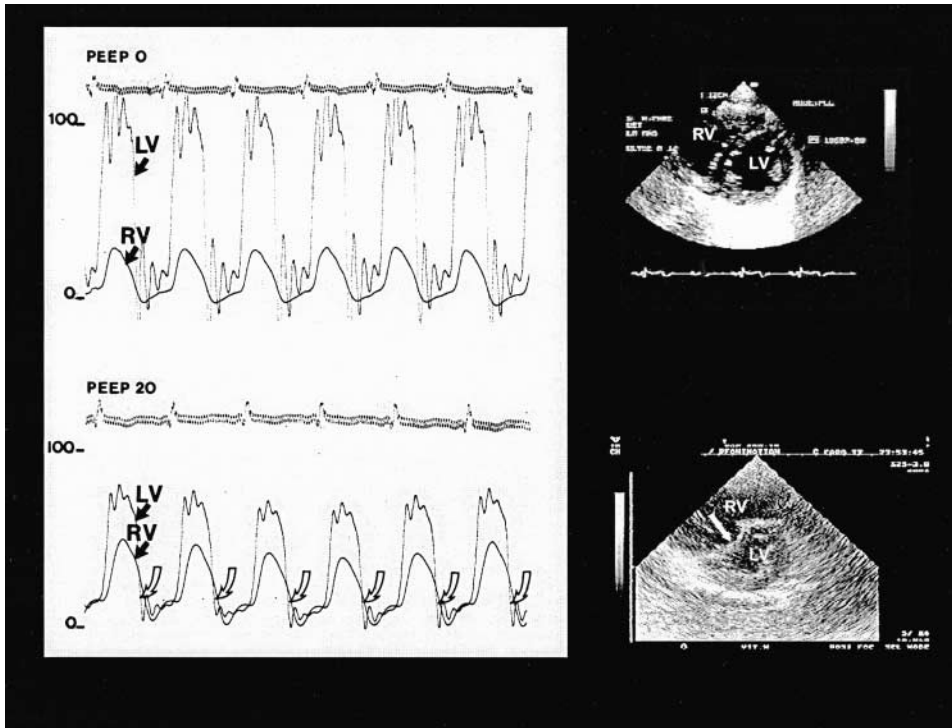
Correspondence and requests for reprints should be addressed to F. Jardin, M.D., Hôpital Ambroise Paré, 9 avenue Charles de Gaulle, 92104 Boulogne Cedex, France. E-mail: francois.jardin@apr.ap-hop-paris.fr

This article has an online data supplement, which is accessible from this issue's table of contents online at [www.atsjournals.org](http://www.atsjournals.org)

Am J Respir Crit Care Med Vol 166. pp 1310-1319, 2002

DOI: 10.1164/rccm.200202-146CC

Internet address: [www.atsjournals.org](http://www.atsjournals.org)

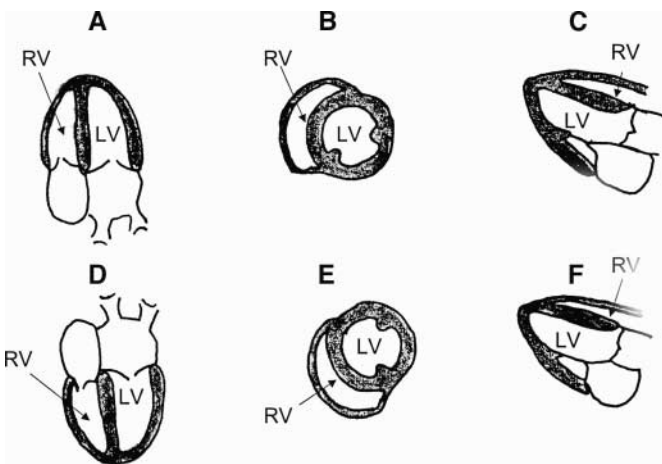


**Figure 1.** Effect of an acute increase in right ventricular impedance on the trans-septal pressure gradient in a patient receiving mechanical ventilation for acute respiratory distress syndrome, and its consequences on septal position. *Left:* Left and right ventricular pressures were simultaneously recorded (LV = left ventricle; RV = right ventricle) at a PEEP of 0 cm H<sub>2</sub>O (top) and at a PEEP of 20 cm H<sub>2</sub>O (bottom). Note that right ventricular pressure becomes higher than left ventricular pressure (open arrows) at end systole/onset diastole during PEEP ventilation. *Right:* A simultaneous short-axis examination of the septal shape. Note septal flattening with PEEP (white arrow).

ventricular systole, occurring at a moment when the left ventricle starts to relax, reverses the left-to-right pressure gradient at end systole/onset diastole, which results in septal dyskinesia (Figure 1). The interventricular septum is displaced leftward at the onset of left ventricular diastole, and suddenly returns rightward when the left ventricle resumes contraction, resulting in a paradoxical motion (5–8). If the right ventricular filling pressure is higher than the left—which is regularly the case in this setting because diastolic overload is usually associated with systolic overload—septal displacement and flattening persist through diastole, and a sudden return of the interventricular septum toward the right

ventricular cavity is produced only when left ventricular pressure exceeds right ventricular pressure, at the onset of systole (7). Examination of septal shape and kinetics indicates right ventricular systolic overload (7). An accurate analysis is obtained by M-mode study in the parasternal short-axis view (Figure 3). This analysis is not possible by transesophageal echocardiography because the M-mode cannot cross the interventricular septum. However, a frame-by-frame analysis can demonstrate septal dyskinesia (see Film 1B in the online data supplement).

In response to a persistent acute pressure overload, significant changes develop in the configuration and the functional characteristics of the right ventricle. In a long-axis view, the apical region loses its triangular shape and becomes more rounded (Figure 4, Film 5). In the short axis, the right ventricular cavity loses its crescent shape and becomes oval by septal displacement (Figure 4, Film 5). This change in configuration makes the right

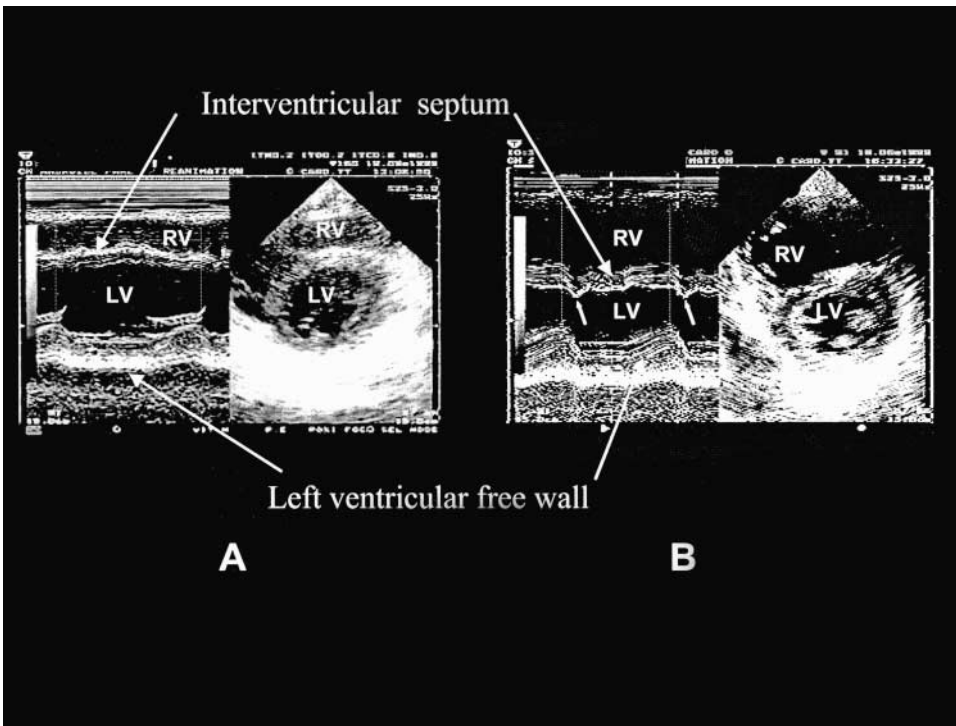


**Figure 2.** The main views used to study the right ventricle are summarized here. *Top:* Transthoracic examination, including an apical four-chamber view (A), a parasternal short-axis view (B), and an oblique parasternal view (C). *Bottom:* A long-axis transesophageal view (D), a short-axis transgastric view (E), and an oblique transgastric view (F). RV = Right ventricle; LV = left ventricle.

**TABLE 1. REPRODUCIBILITY OF ECHO-DOPPLER MEASUREMENT USED TO ASSESS RIGHT VENTRICULAR FUNCTION**

	Intraobserver Variability (%)	Interobserver Variability (%)
RVEDA/LVEDA	6 ± 5	8 ± 5
PA <sub>VTI</sub>	9 ± 6	10 ± 2
ACT	6 ± 7	14 ± 6
FP	3 ± 2	8 ± 9
ACT/FP	7 ± 5	20 ± 15
E/A mitral	9 ± 7	11 ± 8

*Definition of abbreviations:* ACT = acceleration time (time interval between onset of right ventricular ejection and peak velocity in right ventricular outflow tract); E/A mitral = ratio between peak velocity of E wave (early ventricular filling) and A wave (late ventricular filling by atrial systole), at the mitral level; FP = flow period (duration of right ventricular ejection); PA<sub>VTI</sub> = pulmonary artery velocity-time integral; RVEDA/LVEDA = ratio of right ventricular end-diastolic area to left ventricular end-diastolic area (or diastolic ventricular ratio).

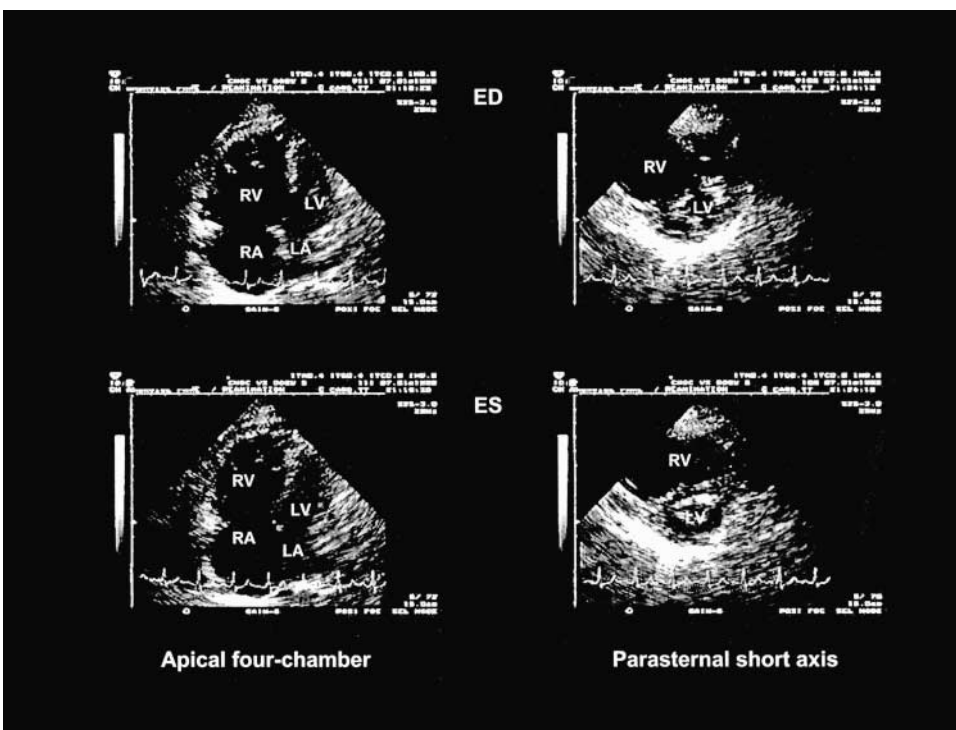


**Figure 3.** Examination of septal kinetics by parasternal short-axis view, coupling two-dimensional and M-mode studies. (A) Normal pattern of septal movement. (B) Acute cor pulmonale complicating massive pulmonary embolism, with a typical septal dyskinesia, the interventricular septum moving toward the center of the left ventricular cavity at the onset of diastole, as indicated by arrows. The dashed lines exactly indicate end-systole. LV = Left ventricular cavity; RV = right ventricular cavity. Also note the major RV enlargement in (B).

ventricular cavity more like the left (Figure 4, Film 5). Doppler examination of pulmonary artery flow velocity reveals that the acceleration time/flow period ratio is reduced (Table 2). Sudden and major pressure overload producing a low-flow state markedly reduces pulmonary artery flow velocity (Figure 5). A biphasic pattern is also frequently observed, with a midsystolic reduction in velocity (Figure 5). Progressive or persistent acute pressure overload makes pulmonary artery flow velocity like

aortic flow velocity, with an increased and premature peak velocity (Table 2 and Figure 6).

Normal right ventricular diastolic thickness measured by a transthoracic approach has been established in one clinical study as  $3.3 \pm 0.6$  mm (mean  $\pm$  SD) (9), and in another as  $2.8 \pm 1$  mm (mean  $\pm$  SD) (10). Using the transesophageal approach, we have observed a significant increase in right ventricular diastolic thickness after 48 hours of respiratory support in patients with



**Figure 4.** Acute changes in the right ventricular (RV) cavity in a patient exhibiting acute cor pulmonale complicating massive pulmonary embolism. In addition to a major enlargement of RV and right atrial (RA) cavities at both end diastole (ED) and end systole (ES), an apical four-chamber view demonstrates that the triangular apex becomes more rounded. In a short-axis view, the RV cavity appears oval. LA = Left atrial cavity; LV = left ventricular cavity. (See also Films 5A and 5B in the online data supplement.)

**TABLE 2. PULSED DOPPLER ANALYSIS OF PULMONARY BLOOD FLOW IN NORMAL VOLUNTEERS AND IN SUBJECTS WITH ACUTE COR PULMONALE**

	Normal Volunteers (n = 24)	ACP Complicating ARDS (n = 19)	ACP Complicating MPE (n = 18)
PA <sub>vTI</sub> , cm	18 ± 3	11 ± 4*	9 ± 3*
Peak velocity, m/s	0.80 ± 0.20	0.82 ± 0.21	0.64 ± 0.17*
ACT, ms	125 ± 23	76 ± 27*	68 ± 36*
FP, ms	304 ± 23	244 ± 32*	252 ± 32*
ACT/FP, %	41 ± 7	32 ± 13*	25 ± 8*

Definition of abbreviations: ACP = acute cor pulmonale; ACT = acceleration time; ARDS = acute respiratory distress syndrome; FP = flow period; MPE = massive pulmonary embolism; PA<sub>vTI</sub> = pulmonary artery velocity–time integral; peak velocity = peak velocity of pulmonary artery blood flow.

\* p < 0.05, compared with normal volunteers.

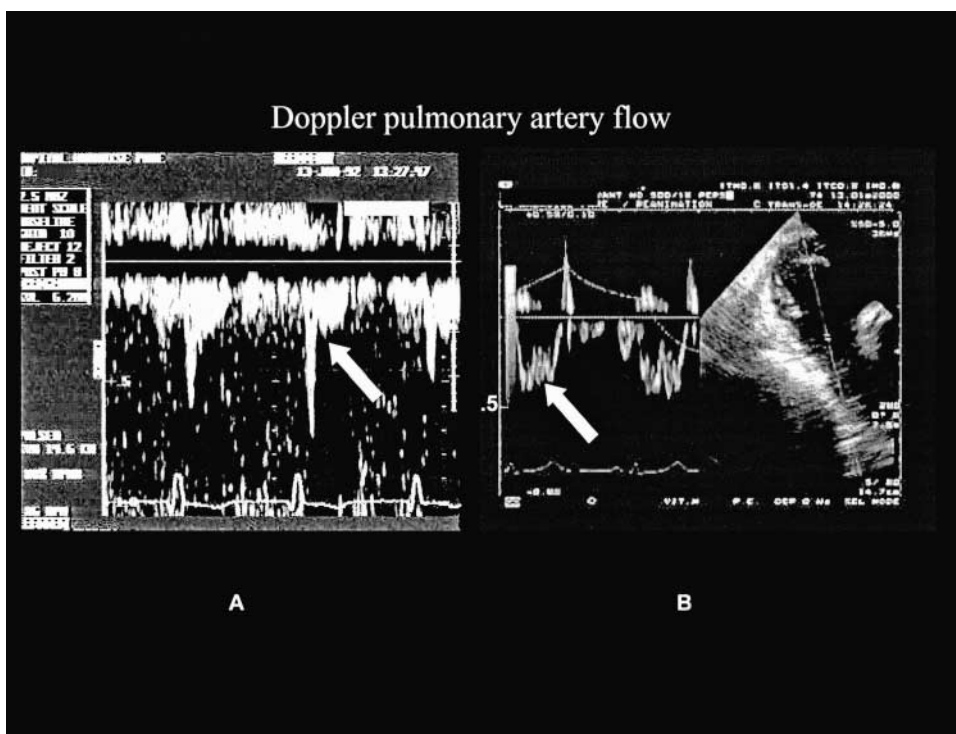
acute respiratory distress syndrome and exhibiting acute cor pulmonale, with an average value of  $6.5 \pm 1.5$  mm (mean  $\pm$  SD) (Figure 7). This finding suggests that, like other mammals, humans may rapidly increase their right ventricular muscular mass in response to pressure overload. Katamaya and coworkers (11) inserted a balloon into the pulmonary artery of lambs, and they inflated the balloon for 2 hours twice daily. After 4 days of this procedure (i.e., a total of 16 hours of intermittent right ventricular afterloading), they observed a significant increase in the myocardial mass of the right ventricle. In patients with acute respiratory distress syndrome, 48 hours of mechanical ventilation with an inspiratory/expiratory ratio of 1/2 also produce 16 hours of intermittent right ventricular afterloading.

Severe right ventricular pressure overload causes a drop in cardiac stroke output, which may be measured by both aortic and pulmonary artery velocity–time integral. Whereas the normal value of pulmonary artery velocity–time integral by pulsed Doppler in a group of 24 normal volunteers was found to be  $18 \pm 3$  cm (mean  $\pm$  SD) (12), we found markedly reduced values in acute cor pulmonale complicating both acute respiratory distress syndrome and massive pulmonary embolism (Table 2).

By analogy with the left side, it is attractive to evaluate right ventricular systolic function by measuring the fractional area contraction in a long-axis view, which is easily obtained from an apical or a transesophageal approach. Right ventricular fractional area contraction is calculated as right ventricular end-diastolic area minus right ventricular end-systolic area, divided by right ventricular end-diastolic area. However, the large range of normal values (40 to 74% in our laboratory [13], 30 to 60% in Weyman's laboratory [14]), and the lack of correlation with pulmonary artery systolic pressure or angiographic obstruction index in pathologic conditions (15, 16), make the fractional area contraction of little value in clinical practice.

#### ECHO-DOPPLER DEMONSTRATION OF RIGHT VENTRICULAR DIASTOLIC OVERLOAD: RIGHT VENTRICULAR ENLARGEMENT

A normal right ventricle has an end-diastolic volume similar to that of the left ventricle (17, 18). Because of its regular shape, left ventricular volume can easily be measured by two-dimensional echocardiography, even with a monoplane formula (19), and a



**Figure 5.** Continuous (A) or pulsed (B) Doppler examination of pulmonary artery flow at the level of the RV outflow tract. (A) Acute cor pulmonale complicating massive pulmonary embolism; (B) acute cor pulmonale complicating acute respiratory distress syndrome. Both patients had a low cardiac output requiring vasoactive support. Note the premature peak velocity with a reduced maximal velocity (0.5 to 0.7 m/second in [A], 0.4 m/second in [B]) and the biphasic pattern of the Doppler profile (arrows).

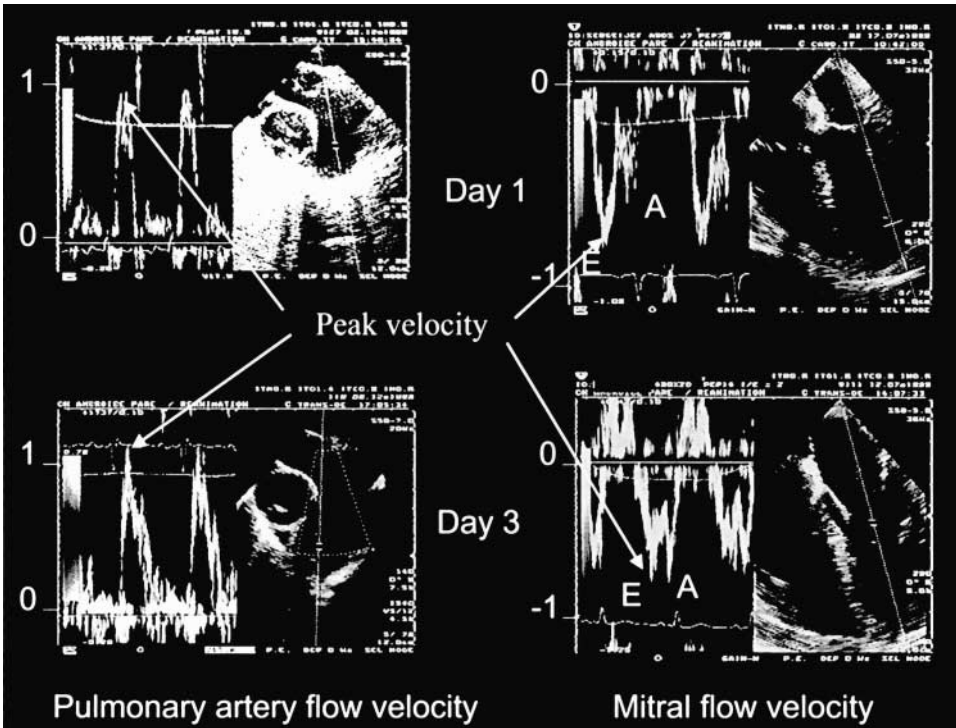


Figure 6. Simultaneous change in Doppler pulmonary artery (left) and in mitral (right) flow velocity profile in a patient with acute respiratory distress syndrome between Day 1 (the first day of mechanical ventilation) and Day 3 (after 48 hours of mechanical ventilation with airway pressure limited to 28 cm H<sub>2</sub>O). Both flows exhibited a normal pattern on Day 1. On Day 3, acute cor pulmonale was present, with an increased and premature peak velocity of pulmonary artery flow (more than 1 m/second) and equalization of E and A peak velocity on mitral flow, indicating impaired LV relaxation.

normal left ventricular end-diastolic volume is close to 70 cm<sup>3</sup>/m<sup>2</sup> (19, 20). Conversely, its irregular shape makes measurements of right ventricle volume via echocardiography cumbersome. Despite several attempts using two planes, this evaluation has not gained acceptance in clinical practice. However, an accurate measurement of the absolute value of right ventricular volume is not necessary in clinical settings, whereas an accurate diagnosis

of dilatation and a quantitative approach to monitoring its evolution are essential.

Right ventricular diastolic dimensions can be obtained by measuring right ventricular end-diastolic area in the long axis, from an apical four-chamber view, or by a transesophageal approach (1, 10, 21–23). Because pericardial constraint necessarily results in left ventricular restriction when the right ventricle

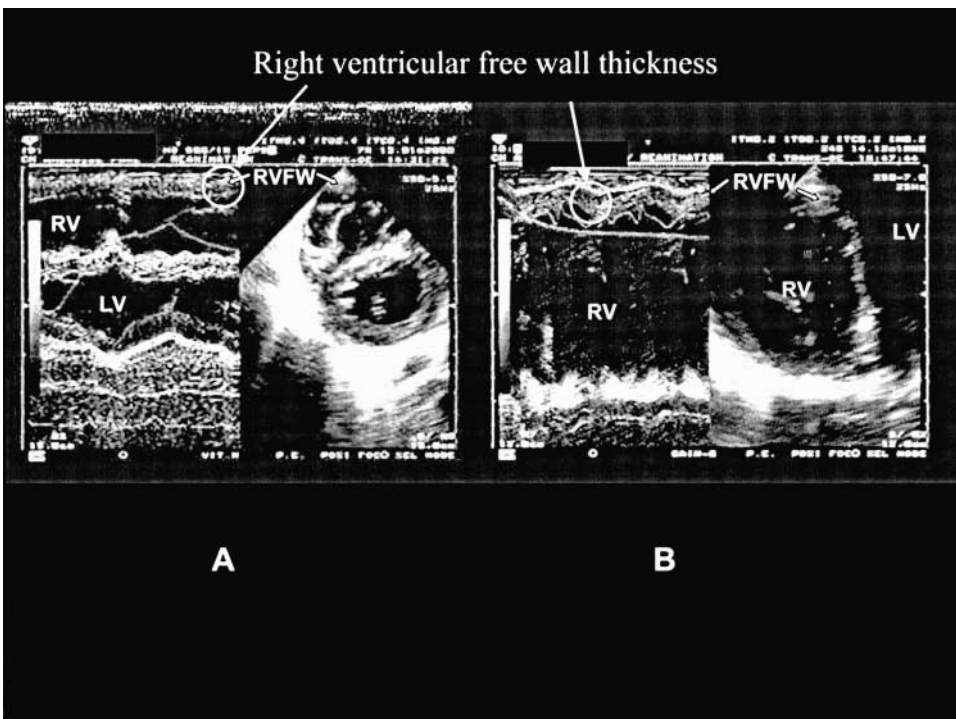


Figure 7. Measurement of right ventricular free wall (RVFW) thickness, coupling two-dimensional imaging along the short axis by a transgastric approach and M-mode study of two patients with acute cor pulmonale complicating acute respiratory distress syndrome. (A) RVFW thickness was 10 mm after 1 week of mechanical ventilation in a patient with extensive bacterial pneumonia. (B) RVFW thickness was 8 mm after 2 days of mechanical ventilation in a patient with viral (varicella) pneumonia. Both patients had normal RVFW thickness on echocardiography 6 months later, by a transthoracic approach (3.5 and 3.2 mm, respectively). LV = Left ventricle; RV = right ventricle.

**TABLE 3. AVERAGE HEMODYNAMIC AND ECHO-DOPPLER DATA OBTAINED IN THREE GROUPS OF PATIENTS WITH ACUTE RESPIRATORY DISTRESS SYNDROME**

	No ACP* (n = 62)	Moderate ACP† (n = 13)	Severe ACP‡ (n = 6)
RVEDA/LVEDA	0.54 ± 0.12	0.81 ± 0.10 <sup>§</sup>	1.2 ± 0.11 <sup>§</sup>
HR, beats/min	100 ± 18	114 ± 9	100 ± 17
SI (Doppler), cm <sup>3</sup> /m <sup>2</sup>	32 ± 9	25 ± 8 <sup>§</sup>	21 ± 4 <sup>§</sup>
CI (Doppler), L/min/m <sup>2</sup>	3.1 ± 0.9	2.8 ± 0.8	2 ± 0.8 <sup>§</sup>
RVEDA, cm <sup>2</sup> /m <sup>2</sup>	8.6 ± 2.1	11.6 ± 2.8 <sup>§</sup>	15.2 ± 3.5 <sup>§</sup>
RVESA, cm <sup>2</sup> /m <sup>2</sup>	5.6 ± 1.9	7.6 ± 2.2 <sup>§</sup>	11.7 ± 2.2 <sup>§</sup>
LVEDV, cm <sup>3</sup> /m <sup>2</sup>	61 ± 16	45 ± 8 <sup>§</sup>	43 ± 10 <sup>§</sup>
LVESV, cm <sup>3</sup> /m <sup>2</sup>	29 ± 10	22 ± 10 <sup>§</sup>	20 ± 8 <sup>§</sup>
LVEF, %	52 ± 11	52 ± 17	53 ± 14
Ppa,s (Doppler), mm Hg	28 ± 11	51 ± 3 <sup>§</sup>	44 ± 6 <sup>§</sup>
E/A mitral	1.3 ± 0.4	0.8 ± 0.2	0.8 ± 0.1
IVC, diam mm	17 ± 5	19 ± 7	24 ± 3

*Definition of abbreviations:* ACP = acute cor pulmonale; CI = cardiac index; E/A = peak velocity of the E wave/peak velocity of the A wave of the mitral flow; HR = heart rate; IVC diam = inferior vena caval diameter; LVEDV = left ventricular end-diastolic volume; LVEF = left ventricular ejection fraction; LVESV = left ventricular end-systolic volume; Ppa,s = systolic pulmonary artery pressure; RVEDA = right ventricular end-diastolic area; RVEDA/LVEDA = right ventricular end-diastolic area/left ventricular end-diastolic area ratio (or diastolic ventricular ratio); RVESA = right ventricular end-systolic area; SI = stroke index.

\* No ACP: 62 patients without acute cor pulmonale.

† Moderate ACP: 13 patients with moderate acute cor pulmonale (0.6 < RVEDA/LVEDA ratio < 1).

‡ Severe ACP: six patients with severe acute cor pulmonale (RVEDA/LVEDA ratio ≥ 1).

§ p < 0.05, versus No ACP.

acutely dilates, the best way to quantify right ventricular dilatation is to measure the ratio between the right and left ventricular end-diastolic areas, which circumvents individual variations in cardiac size. We found this diastolic ventricular ratio to be 0.48 ± 0.12 (mean ± SD) in a group of normal volunteers (16). We have thus defined moderate RV dilatation as a diastolic ventricu-

lar ratio greater than 0.6, and major right ventricular dilatation as a diastolic ventricular ratio greater than or equal to 1 (1). Significant right ventricular enlargement is observed in acute cor pulmonale complicating both acute respiratory distress syndrome and massive pulmonary embolism (Tables 3 and 4) (15, 16).

Right ventricular diastolic enlargement is usually associated with right atrial dilatation (Figure 4), inferior vena caval dilatation, and tricuspid regurgitation. When pressure in the right atrium exceeds that in the left atrium, the foramen ovale may open. Detection of a patent foramen ovale requires contrast echocardiography, and has been greatly improved by transesophageal echocardiography (24).

Measurement of the maximal velocity of tricuspid backward flow when regurgitation is present allows estimation of pulmonary artery systolic pressure (Figure 8). A moderate elevation is observed in acute cor pulmonale complicating both acute respiratory distress syndrome and massive pulmonary embolism (Tables 3 and 4) (15, 16). However, in an individual patient, this measurement is of limited value because systolic pulmonary artery pressure also depends on right ventricular stroke output.

### LEFT VENTRICULAR CONSEQUENCES OF ACUTE COR PULMONALE

Sudden right ventricular enlargement in the stiff pericardial space causes left ventricular compression. Whereas the normal left ventricular end-diastolic volume according to the area-length formula is close to 70 cm<sup>3</sup>/m<sup>2</sup> by an apical window (19, 20), and nearly 62 cm<sup>3</sup>/m<sup>2</sup> by a transesophageal approach (20), we have observed severe reduction in acute cor pulmonale (Tables 3 and 4) (15, 16). This acute preload deficit, which is more sudden and more marked in massive pulmonary embolism, often produces acute circulatory failure in this setting (16). Even if more progressive, it may also precipitate circulatory failure in acute respiratory distress syndrome (Films 2, 3, and 6A). Left ventricular filling impairment in acute cor pulmonale results from com-

**TABLE 4. HEMODYNAMIC AND ECHO-DOPPLER DATA OBTAINED IN THREE GROUPS OF PATIENTS WITH MASSIVE PULMONARY EMBOLISM**

	No Circulatory Failure* (n = 32)	Circulatory Failure without Acidosis† (n = 32)	Circulatory Failure with Acidosis‡ (n = 34)
RVEDA/LVEDA	1 ± 0.2	1.2 ± 0.3	1.4 ± 0.5 <sup>§</sup>
HR, beats/min	88 ± 12	104 ± 14 <sup>§</sup>	109 ± 18 <sup>§</sup>
SI (Doppler) cm <sup>3</sup> /m <sup>2</sup>	31 ± 8	22 ± 8 <sup>§</sup>	18 ± 8 <sup>§</sup>
CI (Doppler), L/min/m <sup>2</sup>	2.7 ± 0.7	2.2 ± 0.7	1.9 ± 0.9 <sup>§</sup>
RVEDA, cm <sup>2</sup> /m <sup>2</sup>	15.8 ± 4.5	15.7 ± 3.3	15.9 ± 4
RVESA, cm <sup>2</sup> /m <sup>2</sup>	11.7 ± 3.8	11.7 ± 3.1	12 ± 3.3
LVEDV, cm <sup>3</sup> /m <sup>2</sup>	54.3 ± 11.3	41.3 ± 15.2 <sup>§</sup>	37.7 ± 19.7 <sup>§</sup>
LVESV, cm <sup>3</sup> /m <sup>2</sup>	26.4 ± 13.1	17.4 ± 7.8	19.8 ± 13.4
LVEF, %	54 ± 15	58 ± 11	49 ± 12
Ppa,s (Doppler), mm Hg	55 ± 18	48 ± 15	48 ± 16
E/A mitral	0.85 ± 0.26	0.80 ± 0.21	0.78 ± 0.20
IVC diam, mm	16 ± 6	19 ± 6	19 ± 5

Reprinted by permission from Vieillard-Baron A, Page B, Augarde R, Prin S, Qanadli S, Beauchet A, Dubourg O, Jardin F. Acute cor pulmonale in massive pulmonary embolism: incidence, echocardiographic pattern, clinical implications and recovery rate. *Intensive Care Med* 2001;27:1481-1486 (16).

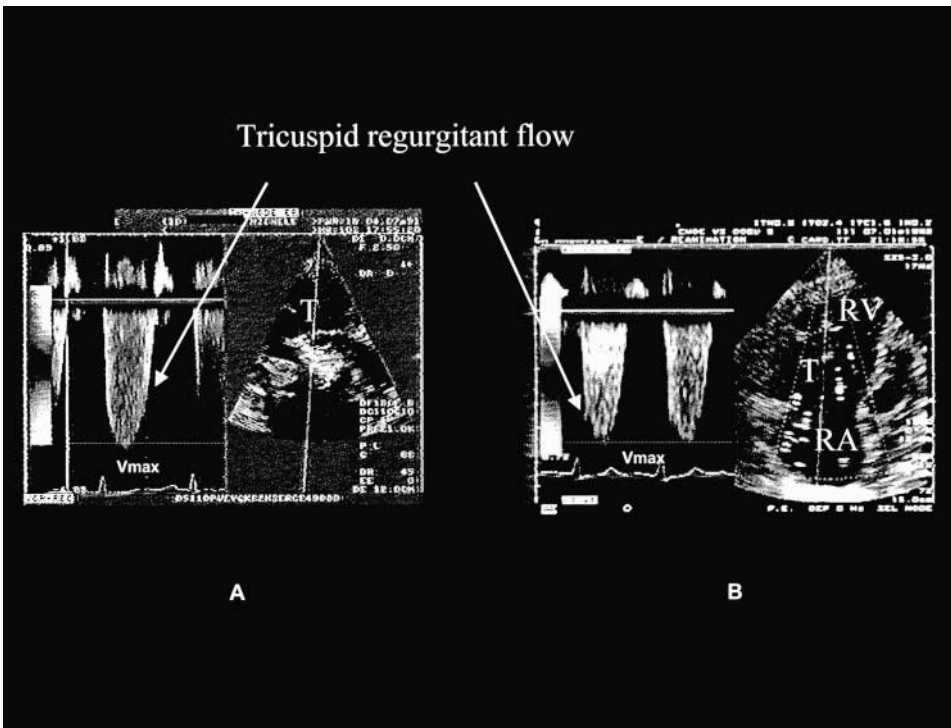
*Definition of abbreviations:* ACP = acute cor pulmonale; CI = cardiac index; E/A = peak velocity of the E wave/peak velocity of the A wave of the mitral flow; HR = heart rate; IVC diam = inferior vena caval diameter; LVEDV = left ventricular end-diastolic volume; LVEF = left ventricular ejection fraction; LVESV = left ventricular end-systolic volume; Ppa,s = systolic pulmonary artery pressure; RVEDA = right ventricular end-diastolic area; RVEDA/LVEDA = right ventricular end-diastolic area/left ventricular end-diastolic area ratio (or diastolic ventricular ratio); RVESA = right ventricular end-systolic area; SI = stroke index.

\* No circulatory failure: 32 patients with a systolic arterial pressure > 90 mm Hg without vasoactive support.

† Circulatory failure without acidosis: 32 patients with a systolic arterial pressure > 90 mm Hg with vasoactive support.

‡ Circulatory failure with acidosis: 34 patients exhibiting metabolic acidosis (base deficit > 5 mM) despite vasoactive support.

§ p < 0.05, versus group with no circulatory failure.



**Figure 8.** Continuous wave Doppler examination of tricuspid regurgitant flow. (A) In a patient with acute cor pulmonale complicating acute respiratory distress syndrome, peak velocity (Vmax) was 3.2 m/second, resulting in a calculated pressure gradient of 41 mm Hg and a pulmonary artery systolic pressure of 54 mm Hg (central venous pressure was 13 mm Hg). (B) In a patient with acute cor pulmonale complicating massive pulmonary embolism, peak velocity (Vmax) was 2.4 m/second, resulting in a calculated pressure gradient of 23 mm Hg and a pulmonary artery systolic pressure of 39 mm Hg (central venous pressure was 16 mm Hg). RA = Right atrium; RV = right ventricle; T = tricuspid flow.

bined pulmonary vascular occlusion and septal displacement (6). The latter produces abnormal left ventricular relaxation, which is also evidenced by an abnormal mitral flow profile, with a pre-eminent peak velocity during atrial systole (Figure 6). When calculating the ratio of peak velocity during early diastolic filling (E wave) for peak velocity of the atrial systole (A wave), we found an inverted ratio in acute cor pulmonale complicating both acute respiratory distress syndrome and massive pulmonary embolism (Tables 3 and 4) (15, 16).

#### LIMITATIONS OF DIASTOLIC VENTRICULAR RATIO IN GRADING RIGHT VENTRICULAR DILATATION

Cor pulmonale was first described as a long-term complication of chronic obstructive pulmonary disease. Echocardiographic abnormalities associated with chronic cor pulmonale share many similarities with those of acute cor pulmonale (25), but also two prominent differences: first, there is a marked increase in right ventricular diastolic wall thickness (which is usually greater than 9 mm at end diastole), associated with marked intracavity muscle trabeculations (25). Second, there is left ventricular hypertrophy, involving both the interventricular septum and free wall (26).

Right ventricular cavity enlargement may also be observed in more than 50% of patients exhibiting right ventricular infarction, and be graded by diastolic ventricular area ratio measurement. While the clinical context is usually clearly different, the echocardiographic pattern might be confused with that of acute cor pulmonale. In this setting, the presence of left ventricular posterior or inferior free wall abnormalities usually allows the two conditions to be distinguished (27).

Finally, gradation of right ventricular dilatation by ventricular diastolic area ratio may be inoperative when chronic left ventricular dilatation is present, because of valvular disease or dilated cardiomyopathy.

#### ACUTE COR PULMONALE IN MASSIVE PULMONARY EMBOLISM

Massive pulmonary embolism, that is, pulmonary embolism involving at least two lobar arteries, is the first cause of acute cor pulmonale. The invaluable aid provided by echocardiography in the evaluation of massive pulmonary embolism was first described by Kasper and coworkers (28), and several authors have described measurements different from those proposed here, to quantify right ventricular dysfunction. These authors have proposed the diastolic ventricular diameter ratio (28), right ventricular systolic dysfunction (29), or hypokinesia (30) to quantify right ventricular impairment in massive pulmonary embolism. However, as mentioned above, right ventricular enlargement is usually accompanied by a change in apical shape and is not accurately evaluated by diameter measurement. The quantification of systolic dysfunction as proposed by Ribeiro and coworkers is not standardized (29), and hypokinesia (30) is a qualitative parameter that may be somewhat subjective. Moreover, measurement of right ventricular fractional area contraction, as quantitatively evaluated by echocardiography, is weakly related to the severity of circulatory failure, as mentioned above. We thus believe that our echocardiographic definitions, combining an increased diastolic ventricular ratio with septal dyskinesia, is more reliable. Using our definition, we found a 61% incidence of acute cor pulmonale in a group of 161 patients with massive pulmonary embolism proven by angiography or enhanced contrast helicoidal computed tomography (16).

Most patients presenting with massive pulmonary embolism do not require mechanical ventilation, and echocardiographic examination is usually performed via a transthoracic approach. However, in some patients, acute cor pulmonale is diagnosed via a transesophageal approach, after an unexplained cardiac arrest. In such patients, the pulmonary artery thrombus often can be visualized during echocardiographic study (31) (*see Film 4*).

Acute circulatory failure, defined as the requirement for vasopressor support to maintain arterial systolic pressure above 90 mm Hg, is associated with acute cor pulmonale complicating massive pulmonary embolism in two-thirds of cases (16). Several authors have emphasized the poor prognosis of this hemodynamic instability (30, 32). In fact, we have observed in this setting that only patients with metabolic acidosis, defined by a base deficit greater than 5 mMole/L, had a poor prognosis (59% mortality rate), whereas 97% of patients with acute cor pulmonale and no metabolic acidosis eventually recovered, sometimes after several hours of vasopressor support (16).

### **CAN BEDSIDE DEMONSTRATION OF ACUTE COR PULMONALE BY ECHOCARDIOGRAPHY AID CLINICAL DECISION-MAKING IN PATIENTS WITH MASSIVE PULMONARY EMBOLISM?**

Contrast angiography has long remained the “gold” standard for the diagnosis of pulmonary embolism. However, this invasive procedure is not always immediately available and may carry some risks in a patient exhibiting circulatory failure. Bedside echocardiography, by demonstrating the presence of acute cor pulmonale in a suggestive clinical context, markedly increased the probability of a pulmonary embolism and allowed us to initiate specific treatment before definitive confirmation of massive pulmonary embolism by angiography. Enhanced contrast helioidal computed tomography has currently replaced contrast angiography to diagnose pulmonary embolism (33). This less invasive procedure is immediately available in modern hospitals and is usually performed before echocardiography. Thus, when the intensivist performs echocardiography in this context, he or she is usually aware of the diagnosis. The demonstration of acute cor pulmonale would then help assess the hemodynamic tolerance of massive pulmonary embolism and guide subsequent monitoring.

At this time, there is no consensus on the precise indications for thrombolytic therapy in acute cor pulmonale complicating massive pulmonary embolism. Although recommended by some authors (32), and considered to offer no advantages by others (34), thrombolytic therapy was not associated with improved prognosis in our patients presenting with the most severe form of acute cor pulmonale (16). However, the total resolution of RV dilatation, which usually takes between 10 and 20 days (Film 5) (16), is hastened by thrombolytic therapy (Film 6) (16).

### **ACUTE COR PULMONALE IN ACUTE RESPIRATORY DISTRESS SYNDROME**

In the acute respiratory distress syndrome, two factors combine to produce right ventricular systolic overload: the pathologic features of the syndrome per se, which can be associated with distal occlusion of the pulmonary arterial bed (35), and mechanical ventilation, which increases right ventricular outflow impedance (36).

Compared with that required for a normal lung, mechanical ventilation of a diseased lung requires a higher transpulmonary pressure (i.e., alveolar pressure minus pleural pressure), a factor limiting blood flow through the pulmonary capillary bed (37). A normal right ventricle may easily develop a systolic pressure of 25–30 mm Hg. During tidal ventilation, this forward pressure must overcome a backward pressure, that is, the transpulmonary pressure (37), a trivial task when ventilating a normal lung. However, this backward pressure becomes substantial when the lung is damaged. In this setting, persistently high right ventricular

afterload induced by mechanical ventilation may precipitate acute cor pulmonale.

In addition, the application of external positive end-expiratory pressure (PEEP), which increases functional residual capacity by distending undamaged areas, produces increased pulmonary vascular resistance when used above a given level (38). Applying high PEEP levels thus represents another potential factor for increased right ventricular outflow impedance (39, 40).

The occurrence of acute cor pulmonale as a complication of acute respiratory distress syndrome is more progressive and less sudden than in massive pulmonary embolism. It usually requires at least 48 hours of respiratory support (15) (Film 7). We described in 1985 the echocardiographic pattern of acute cor pulmonale complicating acute respiratory distress syndrome (41). At this time, high tidal volumes were used (13 ml/kg) and the incidence of acute cor pulmonale was high (61%) (41). In the most severe forms, where the diastolic ventricular ratio was greater than or equal to 1, we observed a 100% mortality (41). More recently, with airway pressure limitation, the incidence of acute cor pulmonale in acute respiratory distress syndrome has declined to 25% (15). Moreover, with adequate ventilatory management, acute cor pulmonale is not significantly associated with increased mortality (15). Even patients presenting with the most severe form (i.e., with a diastolic ventricular ratio of 1 or more), may recover (15).

### **CAN BEDSIDE DEMONSTRATION OF ACUTE COR PULMONALE BY ECHOCARDIOGRAPHY AID CLINICAL DECISION-MAKING IN PATIENTS WITH ACUTE RESPIRATORY DISTRESS SYNDROME?**

In the past, acute cor pulmonale during adult respiratory distress syndrome was a dreaded complication. Now, with the widespread acceptance of a low-stretch ventilation strategy, the prognosis has improved (42). In our opinion, demonstration of acute cor pulmonale in a patient with adult respiratory distress syndrome should lead the clinician to ask two questions:

1. Is the lung stretch really sufficiently low? All pressure settings should be reexamined, particularly plateau pressure, which should be maintained below 30 cm H<sub>2</sub>O or less if possible. Also PEEP, and particularly intrinsic PEEP, should be reduced. The latter is often caused by an excessive respiratory rate, an insidious cause of right ventricular afterloading (43). If PEEP reduction does not appear possible in the supine position without worsening hypoxemia, prone positioning should be considered.

2. Is it possible to reduce hypercapnia, without increasing tidal volume? In the experimental animal, hypercapnic acidosis has been shown to worsen right ventricular performance (44). Increasing respiratory rate, while reducing the ventilator circuit dead space, may be appropriate, provided it does not produce intrinsic PEEP.

However, in some cases, acute cor pulmonale reflects only the severity of lung injury and may be marginally influenced by the specific maneuvers described above, until respiratory failure improves. At this stage, adding inhaled NO may buy time by temporarily reversing acute cor pulmonale (Film 8).

### **CONCLUSION**

When the circulatory status of a critically ill patient is impaired, clinical evaluation alone is of limited value, and it has long been accepted that additional measurements are often needed. Bedside right heart catheterization using a balloon floating catheter has been available since 1970 and has been largely used in

intensive care units during the following 20 years. Over the past 10 years, the routine practice of this procedure has been questioned.

Echocardiography, an alternative minimally invasive procedure, which provides a dynamic view and can be repeated at the bedside as needed, allows a reasonably accurate hemodynamic evaluation of right ventricular function in patients at risk for acute cor pulmonale in the intensive care unit. Echocardiography can provide useful information for monitoring such patients and their response to therapeutic management.

**Acknowledgment:** The authors gratefully acknowledge Christian Brun-Buisson, M.D., for helping with the presentation of this manuscript.

## References

- Jardin F, Dubourg O, Bourdarias JP. Echocardiographic pattern of acute cor pulmonale. *Chest* 1997;111:209–217.
- Elzinga G, Pienne H, De Jong J. Left and right ventricular pump function and consequences of having two pumps in one heart: a study on isolated cat heart. *Circ Res* 1980;46:564–574.
- Cholley B, Vignon P. Intérêt de l'échocardiographie pour guider le remplissage vasculaire. In: Vignon P, Goarin JP, editors. Echocardiographie Doppler en réanimation, anesthésie et médecine d'urgence. Paris: Elsevier; 2002. p. 83–101.
- Vieillard-Baron A, Augarde R, Prin S, Page B, Beauchet A, Jardin F. Influence of superior vena caval zone conditions on cyclic changes in right ventricular outflow during respiratory support. *Anesthesiology* 2001;95:1083–1088.
- King M, Braun H, Goldblatt A, Liberthson R, Weyman A. Interventricular septal configuration as a predictor of right ventricular systolic hypertension in children: a cross-sectional echocardiography. *Circulation* 1983;68:68–75.
- Jardin F, Dubourg O, Guéret P, Delorme G, Bourdarias JP. Quantitative two-dimensional echocardiography in massive pulmonary embolism: emphasis on ventricular interdependence and leftward septal displacement. *J Am Coll Cardiol* 1987;10:1201–1206.
- Jessup M, Sutton MS, Weber KT, Janicki JS. The effect of chronic pulmonary hypertension on left ventricular size, function, and inter-ventricular septal motion. *Am Heart J* 1987;113:1114–1122.
- Brinker J, Weiss J, Lappé D, Rabson J, Summer W, Permutt S, Weisfeldt M. Leftward septal displacement during right ventricular loading in man. *Circulation* 1980;61:626–633.
- Prakash R, Matsukubo H. Usefulness of echocardiographic right ventricular measurements in estimating right ventricular hypertrophy and right ventricular systolic pressure. *Am J Cardiol* 1983;51:1036–1040.
- Cacho A, Prakash R, Sarma R, Kaushik V. Usefulness of two-dimensional echocardiography in diagnosing right ventricular hypertrophy. *Chest* 1983;84:154–157.
- Katamaya H, Krzeski R, Frantz E, Ferreiro J, Lucas C, Ha B, Henry W. Induction of right ventricular hypertrophy with obstructing balloon catheter: nonsurgical ventricular preparation for the arterial switch operation in simple transposition. *Circulation* 1993;88:1765–1769.
- Delorme G, Dubourg O, Jondeau G, Beauchet A, Arnal JF, Hardy A, Brun D, Dinanian S, Bock F, Bourdarias JP. Etude clinique et échocardiographique en double insu de l'enoximone oral contre placebo dans l'insuffisance cardiaque sévère. *Arch Mal Coeur Vaiss* 1992;85:1023–1029.
- Jardin F. L'évaluation hémodynamique non invasive au lit du patient par l'échocardiographie-Doppler. Paris: Masson; 1995. p. 44.
- Weyman AE, editor. Cross-sectional echocardiography. Philadelphia: Lea & Febiger; 1982. p. 501–502.
- Vieillard-Baron A, Schmitt JM, Augarde R, Fellahi JL, Prin S, Page B, Beauchet A, Jardin F. Acute cor pulmonale in ARDS submitted to protective ventilation: incidence, clinical implications and prognosis. *Crit Care Med* 2001;29:1551–1555.
- Vieillard-Baron A, Page B, Augarde R, Prin S, Qanadli S, Beauchet A, Dubourg O, Jardin F. Acute cor pulmonale in massive pulmonary embolism: incidence, echocardiographic pattern, clinical implications and recovery rate. *Intensive Care Med* 2001;27:1481–1486.
- Marving J, Hoilud-Carlson P, Chraemmer-Jorgensen B, Gadsboll N. Are right and left ventricular ejection fractions equal? *Circulation* 1985;72:502–514.
- Heywood T, Grimm J, Hess O, Jakob M, Krayenbühl H. Right ventricular function during exercise: effect of ischemia. *J Am Coll Cardiol* 1990;16:611–622.
- Triulzi M, Wilkins G, Giliam L, Gentile L, Weyman A. Normal adult cross-sectional echocardiographic values: left ventricular volumes. *Echocardiography* 1985;2:153–169.
- Vieillard-Baron A, Schmitt JM, Beauchet A, Augarde R, Prin S, Page B, Jardin F. Early preload adaptation in septic shock? A transesophageal echocardiographic study. *Anesthesiology* 2001;94:400–406.
- Starling M, Crawford M, Sorensen M, O'Rourke R. A new two-dimensional echocardiographic technique for evaluating right ventricular size and performance in patients with obstructive lung disease. *Circulation* 1982;66:612–620.
- Bommer W, Weinert L, Neumann A, Neff J, Mason D, DeMaria A. Determination of right atrial and right ventricular size by two-dimensional echocardiography. *Circulation* 1979;60:91–100.
- Jardin F, Fellahi JL, Vieillard-Baron A. Exploration échocardiographique du ventricule droit. In: Echocardiographie Doppler en réanimation, anesthésie et médecine d'urgence. Vignon P, Goarin JP, editors. Paris: Elsevier; 2002. p. 158–174.
- Konstadt S, Louie E, Black S, Rao T, Scanlon P. Intraoperative detection of patent foramen ovale by transesophageal echocardiography. *Anesthesiology* 1991;74:212–216.
- Jardin F. Cœur pulmonaire chronique. In: Jardin F, Dubourg O, editors. L'exploration échocardiographique en médecine d'urgence. Paris: Masson; 1986. p. 125–134.
- Jardin F, Guéret P, Prost JF, Farcot JC, Ozier Y, Bourdarias JP. Two-dimensional echocardiographic assessment of left ventricular function in chronic obstructive pulmonary disease. *Am Rev Respir Dis* 1984;129:135–142.
- Guéret P. L'infarctus du myocarde et ses complications. In: Vignon P, Goarin JP, editors. Echocardiographie Doppler en réanimation, anesthésie et médecine d'urgence. Paris: Elsevier; 2002. p. 401–438.
- Kasper W, Meinertz T, Kerstin F, Löllgren H, Limbourg P, Just H. Echocardiography in assessing acute pulmonary hypertension due to pulmonary embolism. *Am J Cardiol* 1980;45:567–572.
- Ribeiro A, Lindmaker P, Juhlin-Dannfelt A, Johnsson H, Jorfeldt L. Echocardiography doppler in pulmonary embolism: right ventricular dysfunction as a predictor of mortality rate. *Am Heart J* 1997;134:479–487.
- Goldhaber S, Visani L, De Rosa M. Acute pulmonary embolism: clinical outcomes in the International Cooperative Embolism Registry (ICOPER). *Lancet* 1999;353:1386–1389.
- Vieillard-Baron A, Qanadli S, Antakly Y, Fourme T, Loubières Y, Jardin F, Dubourg O. Transesophageal echocardiography for the diagnosis of pulmonary embolism with acute cor pulmonale: a comparison with radiologic procedures. *Intensive Care Med* 1998;24:429–433.
- Kasper W, Konstantinides S, Geibel A, Olchewski M, Heinrich F, Grosser K, Rauber K, Iversen S, Redecker M, Kienast J. Management strategies and determinants of outcome in acute major pulmonary embolism: results of a multicenter registry. *J Am Coll Cardiol* 1997;30:1165–1171.
- Qanadli S, El Hajjam M, Vieillard-Baron A, Joseph T, Mesurrolle B, Olivia VL, Barré O, Bruckert F, Dubourg O, Lacombe P. New CT index to quantify arterial obstruction in pulmonary embolism: comparison with angiographic index and echocardiography. *AJR* 2001;76:1415–1420.
- Hamel E, Pacouret G, Vincentelli D, Forissier JF, Peycher P, Pottier JM, Charbonier B. Thrombolysis or heparin therapy in massive pulmonary embolism with right ventricular dilatation. *Chest* 2001;120:120–125.
- Zapol W, Jones R. Vascular component of ARDS: clinical pulmonary hemodynamics and morphology. *Am Rev Respir Dis* 1987;136:471–474.
- Jardin F, Delorme G, Hardy A, Auvert B, Beauchet A, Bourdarias JP. Reevaluation of hemodynamic consequences of positive pressure ventilation: emphasis on cyclic right ventricular afterloading by mechanical lung inflation. *Anesthesiology* 1990;72:966–970.
- Vieillard-Baron A, Loubières Y, Schmitt JM, Page B, Dubourg O, Jardin F. Cyclic changes in right ventricular outflow impedance during mechanical ventilation. *J Appl Physiol* 1999;87:1644–1650.
- Jardin F, Farcot JC, Boisante L, Curien N, Margairaz A, Bourdarias JP. Influence of positive end-expiratory pressure on left ventricular performance. *N Engl J Med* 1981;304:387–392.
- Polaert J, Visser C, Everaert J, DeDeyne C, Decruyenaere J, Colardyn F. Doppler evaluation of right ventricular outflow impedance during positive-pressure ventilation. *J Cardiothorac Vasc Anesth* 1994;8:392–397.
- Schmitt JM, Vieillard-Baron A, Augarde R, Prin S, Page B, Jardin F.

Positive end-expiratory pressure titration in acute respiratory distress syndrome patients: impact on right ventricular outflow impedance evaluated by pulmonary artery Doppler flow velocity measurements. *Crit Care Med* 2001;29:1154–1158.

41. Jardin F, Gueret P, Dubourg O, Farcot JC, Margairaz A, Bourdarias JP. Two-dimensional echocardiographic evaluation of right ventricular size and contractility in acute respiratory failure. *Crit Care Med* 1985; 13:952–956.
42. Scherrer-Crosbie M, Streckenbach S, Zapol W. Acute cor pulmonale in acute respiratory distress syndrome: a dreaded complication of the past? *Crit Care Med* 2001;29:1641–1642.
43. Vieillard-Baron A, Prin S, Augarde R, Desfonds P, Page B, Beauchet A, Jardin F. Increasing respiratory rate to improve CO<sub>2</sub> clearance during mechanical ventilation is not a panacea in acute respiratory failure. *Crit Care Med* 2002;30:1407–1412.
44. Rose E, Van Benthuyzen K, Jackson T, Tucker C, Kaiser D, Grover F, Weil J. Right ventricular performance during increased afterload impaired by hypercapnic acidosis in conscious dogs. *Circ Res* 1983;52: 76–84.